

Case Report



MANAGEMENT OF ATROPHIC-EROSIVE GINGIVAL LICHEN PLANUS WITH TOPICAL AND SYSTEMIC CORTICOSTEROID THERAPY, A CASE REPORT

Shanaz Mohammad Gaphor* and Mustafa Jamel Abdullah**

Submitted: 17/7/2012 ; Accepted 8/2/2013; Published: 1/6/2013

ABSTRACT

The gingiva is a target of autoimmune diseases and about 10% of patients with oral lichen planus have the disease confined to the gingiva, clinically named desquamative gingivitis. The purpose of this paper is to describe 59 year-old female with atrophic-erosive gingival lichen planus that was presented to the Department of Oral Diagnosis, School of Dentistry at Sulaimani University service for evaluation of persistent pain, associated soreness and burning of her gingiva for 3-4 years, which were localized for anterior maxillary region. The histopathological examination confirmed the diagnosis of atrophic-erosive oral lichen planus. The treatment prescribed for the patient was topical and systemic corticosteroid (prednisolone). Substantial improvement was observed in the gingival lesion with reduction in erythema in some regions and complete resolution of pain. The results presented allow the authors to consider the association between local and systemic corticosteroid as a potential therapy for atrophic-erosive gingival lichen planus.

Keywords: *Lichen planus, Corticosteroid, Prednisolone.*

* Oral Medicine Clinic, School of Dentistry, University of Sulaimani. Corresponding email: sgaphor@yahoo.com.

**Oral Medicine Clinic, school of dentistry, University of Sulaimani.

INTRODUCTION

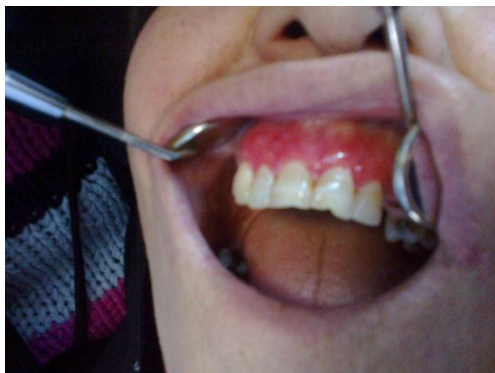
Oral lichen planus (OLP) is a chronic inflammatory mucocutaneous disease with uncertain etiology and auto-immune pathogenesis^(1, 2). The typical age of presentation is between 30-60 years, and the disease is more frequently seen in women⁽³⁾. The most commonly affected sites in OLP are the buccal mucosa, the tongue and the gingiva. Involvement of the palate and the lips is quite rare, and also the floor of the mouth is rarely affected⁽⁴⁾.

Six clinical forms of OLP have been described which are white forms namely reticular, papular, plaque like and the red forms namely the erosive (ulcerated), atrophic (erythematous) and Bullous^(5, 6). Most patients are usually asymptomatic, however burning sensation and pain interference with speaking and eating are common symptoms in the atrophic and erosive forms⁽⁷⁾. Gingival lichen planus can present with reticular, erosive or atrophic subtype⁽⁸⁾ and frequently present with erythematous area or ulceration that affects the entire width of the attached gingiva, a condition

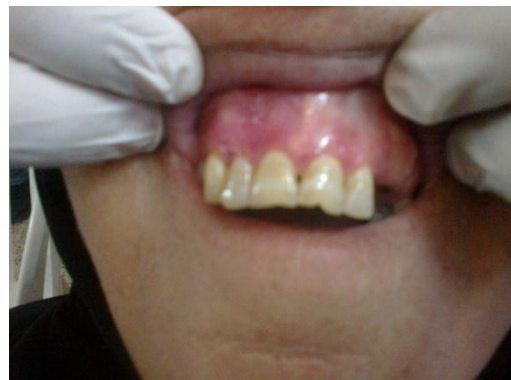
called desquamative gingivitis⁽²⁾. Spontaneous remission is rare and many lesions require treatment⁽⁹⁾. The most widely used agents in treatment are corticosteroids, which can be used topically, intralesionally or systemically⁽⁹⁾. This article describes 59 year old female with the atrophic-erosive gingival lichen planus that were treated with topical and systemic corticosteroid and followed up for 4weeks

CASE REPORT

A 59 year-old female was referred to the Department of Oral Diagnosis, School of Dentistry at Sulaimani University, suffering from persistent pain and associated soreness and burning of her gingiva for 3-4 years. Intraoral examination revealed severe, extensive and erythematous desquamative lesions of the gingiva, which were localized for anterior maxillary region (Figure 1, A). The patient had good oral hygiene and periodontitis was not verified on clinical probing. Incisional biopsy was carried out and the histopathological examination confirmed the diagnosis of atrophic-erosive OLP.



A



B

Figure 1. Clinical aspect of the lichen planus on the upper labial gingiva, pre (A) and post (B) topical and systemic treatment with corticosteroid one month later.

The treatment prescribed for the patient was topical and systemic corticosteroid (60mg) for one week and then the dose was tapered. Prednisolone 20mg three times daily was used in the first week as a topical treatment, it was dissolved in one spoonful of water and used as mouth wash and then swallowed. Twenty mg two times daily were used in the second week, twenty mg one times daily were used in the third week, and 15mg, 10mg, and 5mg one time daily were used respectively in the fourth week. Substantial improvement was observed in the gingival lesion. She was seen weekly till the remission of the gingival lesions, during this period a good healing of gingival lesions was noted with reduction in erythema in some regions and complete resolution of pain (Figure 1, B). She was asked to stop using medication and scheduled for a return at 3 months. The patient reported that acute exacerbations were linked to periods of psychological stress and anxiety.

DISCUSSION

OLP is a chronic inflammatory condition that is probably of multifactorial origin, often idiopathic with an immunopathogenesis involving T-cells⁽¹⁰⁾. The etiopathogenesis of OLP has now been better clarified based on the mechanism involved and appears to be complex, with interactions related to genetic, environmental, and lifestyle factors⁽¹¹⁾. The oral lesions are often a symptomatic but the atrophic erosive form of OLP can cause symptoms ranging from burning sensation to severe pain, resulting in difficulty in speaking, eating, and swallowing⁽¹²⁾. Patients with symptomatic OLP often require therapy to reduce signs and symptoms of the condition⁽¹³⁾. Symptomatic OLP was mainly encountered in those with the erosive form and about 90.9% of the patients had multiple oral sites of involvement. The erosive presentations showed significantly longer duration, more sites are affected (oral, genital, oesophageal)⁽¹⁴⁾.

The gingiva is a target of autoimmune diseases and about 10% of patients with OLP have the disease confined to the gingiva, clinically named desquamative gingivitis (DG)⁽²⁾. However, the clinical appearance of DG is not pathognomonic and may represent the gingival manifestation of many other autoimmune diseases⁽⁸⁾. Exacerbations of DG have been associated with periods of psychological stress, anxiety and mechanical trauma⁽⁹⁾.

There is a large amount of available treatments due to recurrence, high prevalence and risk for malignant transformation of oral lichen planus⁽⁹⁾. Anti-inflammatory agents mainly topical corticosteroids are the most widely used in the treatment of OLP⁽¹⁵⁾. Other therapeutic agents that have been investigated are acitretin, retinoids, immunosuppressants such as cyclosporin, azathioprine, mycophenolate mofetil, tacrolimus and pimecrolimus, thalidomide, interferon alpha, levamisole and phototherapy⁽¹⁾.

Steroids have been found to be effective in treating symptomatic OLP by reducing pain and inflammation. In fact, systemic corticosteroids should be reserved for acute exacerbation, and multiple or widespread lesions. They may be indicated in patients whose condition is unresponsive to topical steroids. However, various potent topical steroids have been reported to be effective in the treatment of symptomatic OLP. They can be used as the first line drugs in the treatment of OLP with no serious side effects⁽¹⁶⁾.

Prednisolone is a corticosteroid with predominant glucocorticoid and low mineralo-corticoid activity, making it useful for the treatment of a wide range of inflammatory and auto-immune conditions (17).

Previous reports have already shown the effectiveness of topical and systemic steroid in the management of OLP⁽¹⁵⁾. The topical use may enhance the local drug absorption; improve the anti-inflammatory action and not leading to undesirable side-effects.

Continuing improvements in topical corticoid formulations aimed at maximizing penetration of the epithelium, will foreseeably improve efficacy. The dosage of systemic steroid therapy must be tailored for individual patients depending on the severity of the lesion, the patient's weight and the patient's response to treatment. When the therapeutic response has been achieved, the dosage of steroid can be rapidly tapered to minimize the significant adverse effects⁽¹⁸⁾.

Patients with atrophic-erosive gingival lichen planus should be monitored throughout life, in view of the chronic nature of this disorder, with frequent reactivations, control of symptoms, burning sensation to severe pain and functional incapacity is particularly important. In summary, topical and systemic corticosteroid was beneficial in the management of severe atrophic-erosive gingival lichen planus.

REFERENCES

1. Agahahosseini F, Arbabi-Kalati F, Fashtami L, Fateh M, Djavid GE. Treatment of oral lichen planus with photodynamic therapy mediated methylene blue: a case report. *Med Oral Patol Oral Cir Bucal* 2006; 1:26-9.
2. Scully C, Carozzo M. Oral mucosal disease: lichen planus. *Br J Oral Maxillofac Surg*. 2008; 46:15-21.
- 3-Nagao T, Ikeda N, Fukano H, Hashimoto S, Shimozato K, Warnakulasuriya S. Incidence rates for oral leukoplakia and lichen planus in a Japanese population. *J Oral Pathol Med* 2005; 34:532-9.
- 4-van der Waal I. Oral lichen planus and oral lichenoid lesions; a critical appraisal with emphasis on the diagnostic aspects. *Med Oral Patol Oral Cir Bucal*. 2009; 14 (7):E310-4.
- 5-Pindborg JJ, Reichart PA, Smith CJ, Van der Waal I. *Histological typing of cancer and precancer of the oral mucosa*. 2nd ed. Springer, New York, 1997; 30.
- 6-Andreasen JO Oral lichen planus .A clinical evaluation of 115 cases. *Oral Surg Oral Med Oral Pathol*. 1968; 25: 31-42.
- 7- Holmstrup P, Schiotz AW, Westergaard J. Effect of dental plaque control on gingival lichen planus. *Oral Surg Oral Med Oral Pathol* 1990; 69:585-90.
- 8-Mignona MD, Lo RL, Fedele S. Gingival involvement of oral lichen planus in a series of 700 patients. *J Clin Periodontol* 2005; 32:1029-1033.
- 9- Ismail SB, Kumar SKS, Zain RB. Oral lichen planus and lichenoid reactions: etiopathogenesis, diagnosis, management, and malignant transformation. *J Oral Sci*. 2007; 49:89-106.
- 10-Scully C, Beyli M, Ferreiro MC, Ficarra G, Gill Y, Griffiths M, Holmstrup P, Mutlu S, Wray D. Update on oral lichen planus: etiopathogenesis and management. *Crit Rev Oral Biol Med* . 1998 ; 9: 86-122.
- 11-Scully C, Eisen D, Carrozzo M. Management of oral lichen planus. *Am J Clin Dermatol*. 2000; 1: 287-306.
- 12-Eisen D. The clinical features, malignant potential, and systemic association of oral lichen planus: a study of 723 patients. *J Am Acad Dermatol*. 2002; 46: 207-214.
- 13-Voute AB, Schulten EA, Langendijk PN, Nieboer C, van der Wall I. Cyclosporin A in an adhesive base for treatment of recalcitrant oral lichen planus. An open trial. *Oral Surg Oral Med Oral Pathol*. 1994; 78: 437-441.
- 14-Xue JL, Fan MW, Wang SZ, Chen XM, Li Y, Wang L. Aclinical study of 674 patients with oral lichen planus in China. *J Oral Pathol Med*. 2005; 34: 467-472.
- 15-Carbone M, Goss E, Carrozo M, Castellano S, Conrotto D, Broccoletti R et al. Systemic and topical corticosteroid treatment of oral lichen planus: a comparative study with long term follow-up. *J Oral Pathol Med*. 2003; 2:323-9.
- 16-Thongprasom K, Dhanuthai K. Sterioids in the treatment of lichen planus: a review.*J Oral Sci*. 2008; 50(4):377-85.
- 17-Czock D, Keller F, Rasche FM, Häussler U. Pharmacokinetics and pharmacodynamics of systemically administered glucocorticoids. *Clin Pharmacokinet*. 2005; 44:61-98.
- 18- Al-Hashimi I, Schifter M, Lockhart PB, Wray D, Brennan M, Migliorati CA, et al. Oral lichen planus and oral lichenoid lesions: diagnostic and therapeutic considerations. *Oral surgery, oral medicine, oral pathology, oral radiology, and endodontics*. 2007;103 Suppl:S25 e1-12.